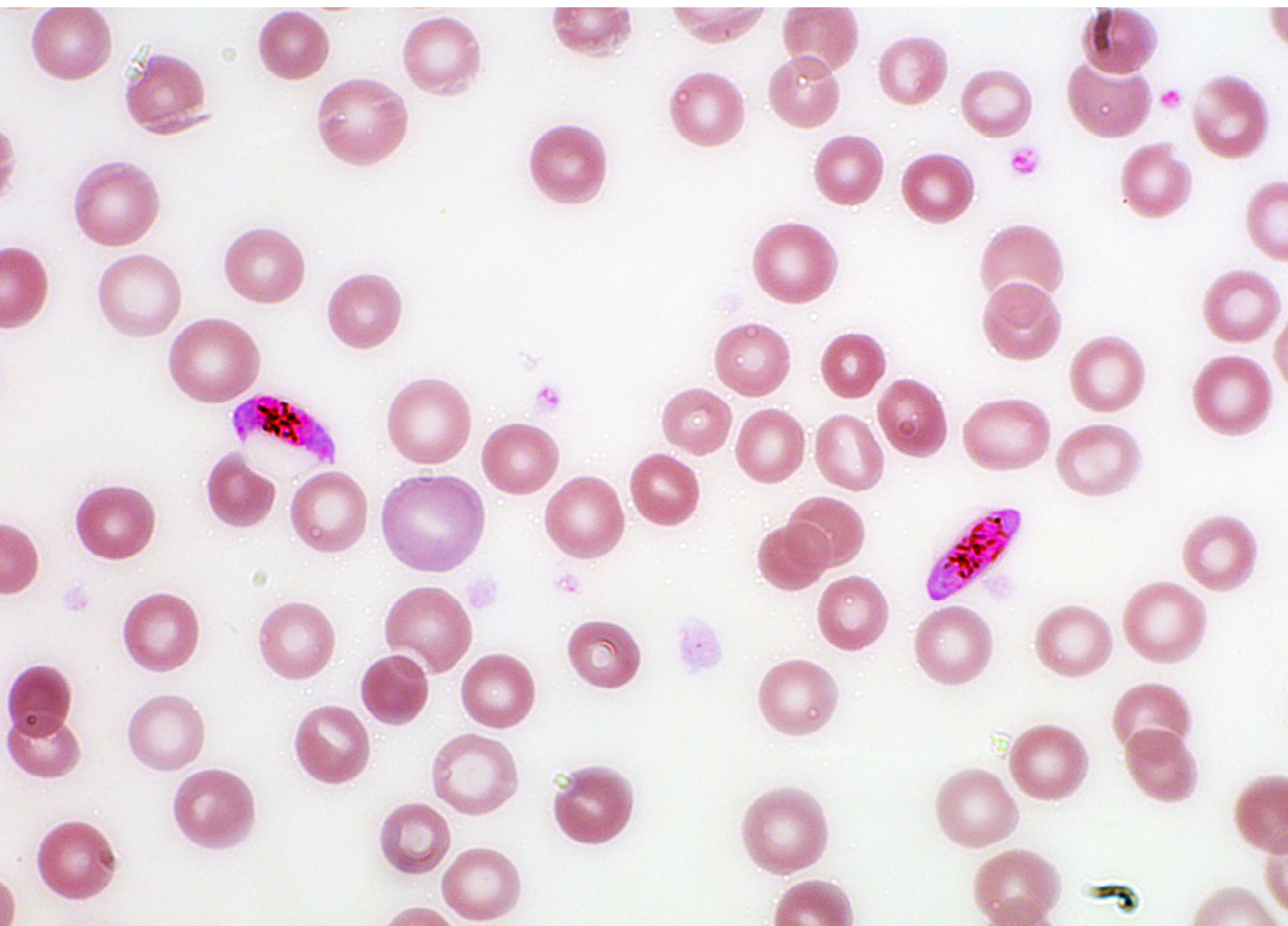

Microscopic Examination of Blood for Malaria Parasites

Microscopic Examination of Blood for Malaria Parasites

Authors: Dr. Gerd-Dieter Burchard
*Specialist for Internal Medicine – Tropical Medicine,
Infectiology, Bernhard Nocht Institute for Tropical
Medicine, Germany*

Dr. Thorsten Kern
Carl Zeiss Microscopy GmbH, Germany

Date: January 2018

Besides tuberculosis, malignant tertian malaria is one of the most widespread infectious diseases affecting humans. Over the course of the past century, it is estimated that 150 to 300 million people have died from malaria. Genetic studies suggest that *Plasmodium falciparum*, the parasite that causes malignant tertian malaria, was transmitted to humans from nonhuman primates, most likely gorillas. It is likely that malaria was even contracted by hunters and gatherers back during the Stone Age – while many other infectious agents only had the opportunity to pass from domesticated pets or rodents to humans after the Neolithic Revolution. While reciprocal adaptation sometimes occurs between parasites and hosts over the course of their coevolution, the relationship between humans and *P. falciparum* can be described as an evolutionary arms race. Today malaria still leads to an estimated 450,000 deaths and 200 million cases of the disease – primarily in children living in Sub-Saharan Africa. A third of the human population lives in areas in which malaria occurs.

Introduction

Numerous studies show that malaria is one of the diseases most often imported by travelers and immigrants. A total of 25,000 cases of the disease and 250 deaths are anticipated each year in industrial countries. The disease is contracted both by tourists and people who work abroad, but also often by immigrants after a trip back home, known as VFR travelers (*visiting friends and relatives*). More than 50 % of the malaria cases in Germany involve such VFR travelers. As such, malaria is a constant concern in the field of travel medicine because:

- It is commonly imported
- It is a life-threatening disease (which can, however, always be treated successfully if diagnosed early)
- It needs to be considered for a number of different symptoms within the scope of differential diagnosis

In cases of malignant tertian malaria or knowlesi malaria, the only way to prevent serious complications and save the patient's life is by rapidly initiating and correctly carrying out treatment.

Because of this, physicians should ask every patient with an unexplained fever whether they have recently spent time abroad and, if applicable, immediately carry out parasitological diagnostic procedures.

How Can the Disease Be Contracted?




Malaria is one of the most common infectious diseases. In the past, malaria occurred up to the Arctic Circle and south to northern Argentina (a malaria epidemic ravaged Arkhangelsk in northern Russia in 1922/1923). Today, its geographic distribution is limited to the tropics and subtropics.

Malaria Prophylaxis

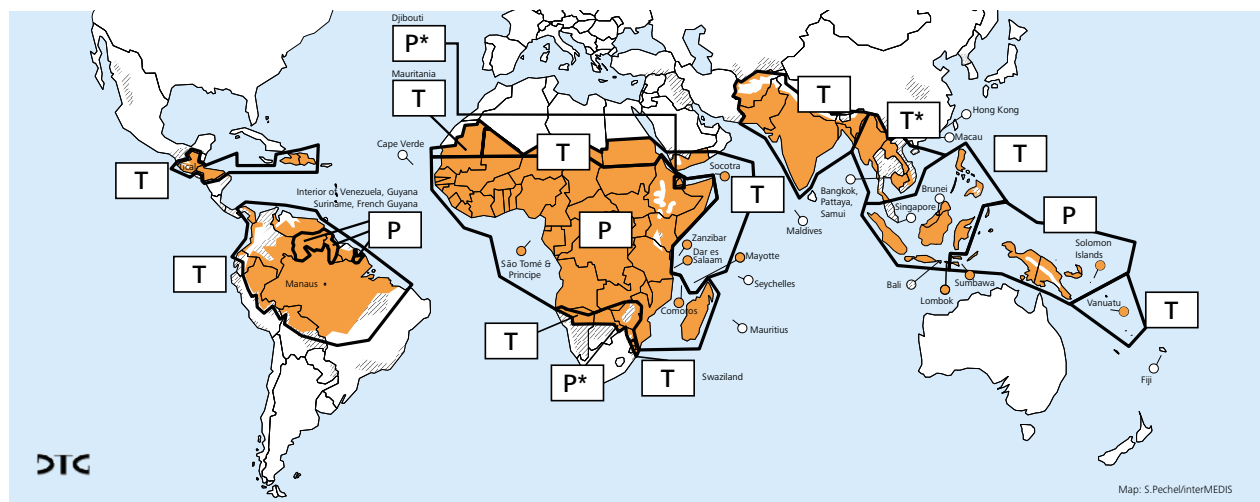
Areas of the world divided into zones based on different medications used for chemoprophylaxis in accordance with the recommendations of the German Society of Tropical Medicine and International Health

Last updated: January 2018

Applicable to all malaria risk areas:
Mosquito repellent is recommended
(minimal risk see country list)

-  Regions in which malaria does not or no longer occurs
-  Regions with extremely low malaria risk (malaria transmission rare)
-  Regions with malaria transmission

- P** For chemoprophylaxis: Atovaquone / Proguanil (Malarone®) or Doxycycline* or Mefloquine (Lariam®)**
* Not approved for use in Germany for these indications
** Observe special warnings
- P*** Seasonal chemoprophylaxis recommended using: Atovaquone / Proguanil (Malarone®) or Doxycycline* or Mefloquine (Lariam®)**
Otherwise, emergency treatment with Atovaquone / Proguanil (Malarone®) or Artemether / Lumefantrine (Riamet®)
* Not approved for use in Germany for these indications
** Observe special warnings
- T** For emergency treatment: Atovaquone / Proguanil (Malarone®) or Artemether / Lumefantrine (Riamet®)
Chemoprophylaxis not recommended
- T*** For emergency treatment: Atovaquone / Proguanil (Malarone®)
Chemoprophylaxis not recommended



Adjusted to WHO,

World Malaria Report 2016; WHO, International Travel and Health 2016; Swiss TPH, Basel/B.R. Beck; University of Zürich/SPMZ; O. Veit

Figure 1 Malaria-endemic regions – courtesy of: DGT

The risk of contracting malaria is highest in tropical Africa, which is where most cases of imported malaria originate. Extensive malaria regions are also found in Brazil and neighboring South American countries. Malaria seldom occurs in Central America. In Haiti and the adjacent areas of the Dominican Republic, malaria only occurs in a single, isolated area of the otherwise malaria-free Caribbean.

In the Middle East, malaria only occurs sporadically. But malaria regions stretch from Pakistan through China into Southeast Asia. In Oceania, malaria primarily affects Papua New Guinea, the Solomon Islands, and Vanuatu.

What Should One Know About the Parasitology of the Pathogen?

Malaria is caused by the single cell parasite plasmodium.

Four types of plasmodium can infect humans:

- *Plasmodium falciparum* causes malignant tertian malaria
- *Plasmodium vivax* and *Plasmodium ovale* cause benign tertian malaria
- *Plasmodium malariae* is responsible for quartan malaria
- *Plasmodium knowlesi* is a malaria pathogen that normally occurs in monkeys in Southeast Asia – but can also cause a life-threatening malaria infection in humans.

Malignant tertian malaria is by far the most dangerous form of the disease and is responsible for almost all of the aforementioned deaths.

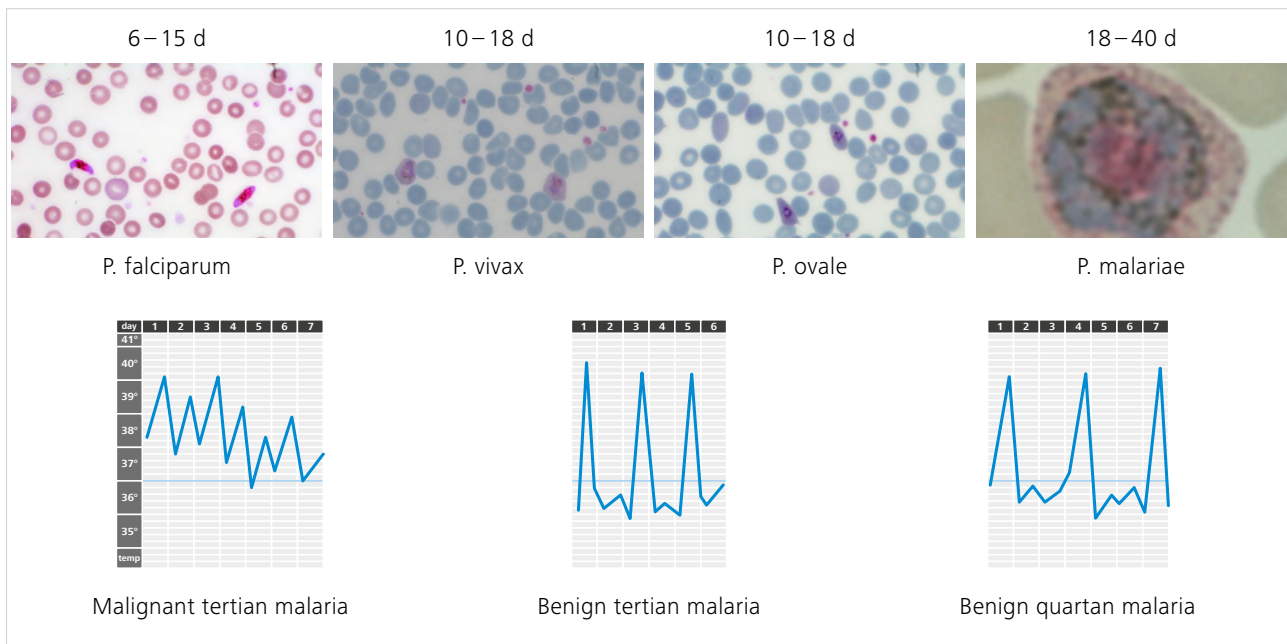


Figure 2 Types of *Plasmodium*

Plasmodium parasites are transmitted through the bite of a female *Anopheles* mosquito. Over the course of its life cycle within the mosquito and human (see Fig. 4, Malaria life cycle), the *Plasmodium* parasite progresses through a series of stages of development, during which it repeatedly changes its external structure.

- With the help of olfactory organs on their antennae, the mosquitoes find a host and use their tubular mouthparts to pierce the skin and vascular wall. They inject an anticoagulant and consume 1–3 µl of blood. During this blood meal, the mosquito injects the infectious stages of the *Plasmodium* parasites – the sporozoites – into the blood stream.

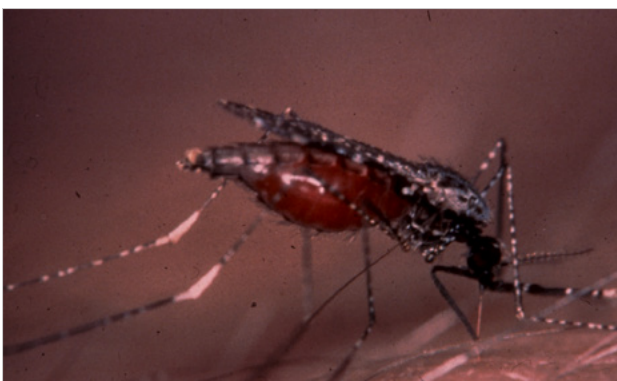

Figure 3 *Anopheles* mosquito

- The sporozoites infect the liver cells within 30–60 minutes, where they transform into a large cell with multiple nuclei, the schizont. This divides into several thousand smaller cells, the merozoites, which are released into the blood stream after one to two weeks (exoerythrocytic stage).
- The merozoites bind to erythrocytes via specific receptors, enter them, and develop through asexual reproduction from trophozoites to preschizonts and then further into schizonts. In this process, 10–20 new merozoites are released, which infect further erythrocytes (erythrocytic stage). *Plasmodium vivax* parasites only invade reticulocytes, while *Plasmodium falciparum* enters erythrocytes of all ages.
- Some merozoites develop into gametocytes, the precursors to male and female gametes. If these are ingested by a mosquito, they undergo sexual reproduction inside the mosquito.

How Does *Plasmodium* Cause Symptoms of the Disease?

The disease is caused by the erythrocytic forms of *Plasmodium*. Tissue schizonts and gametocytes do not play any role. The main components of pathogenesis are anemia, ischemia, immune reactions, and storage phenomenon of the mononuclear phagocyte system (MPS). In individual cases, the organs are involved at different levels of frequency, and this determines the respective patient's clinical aspect.

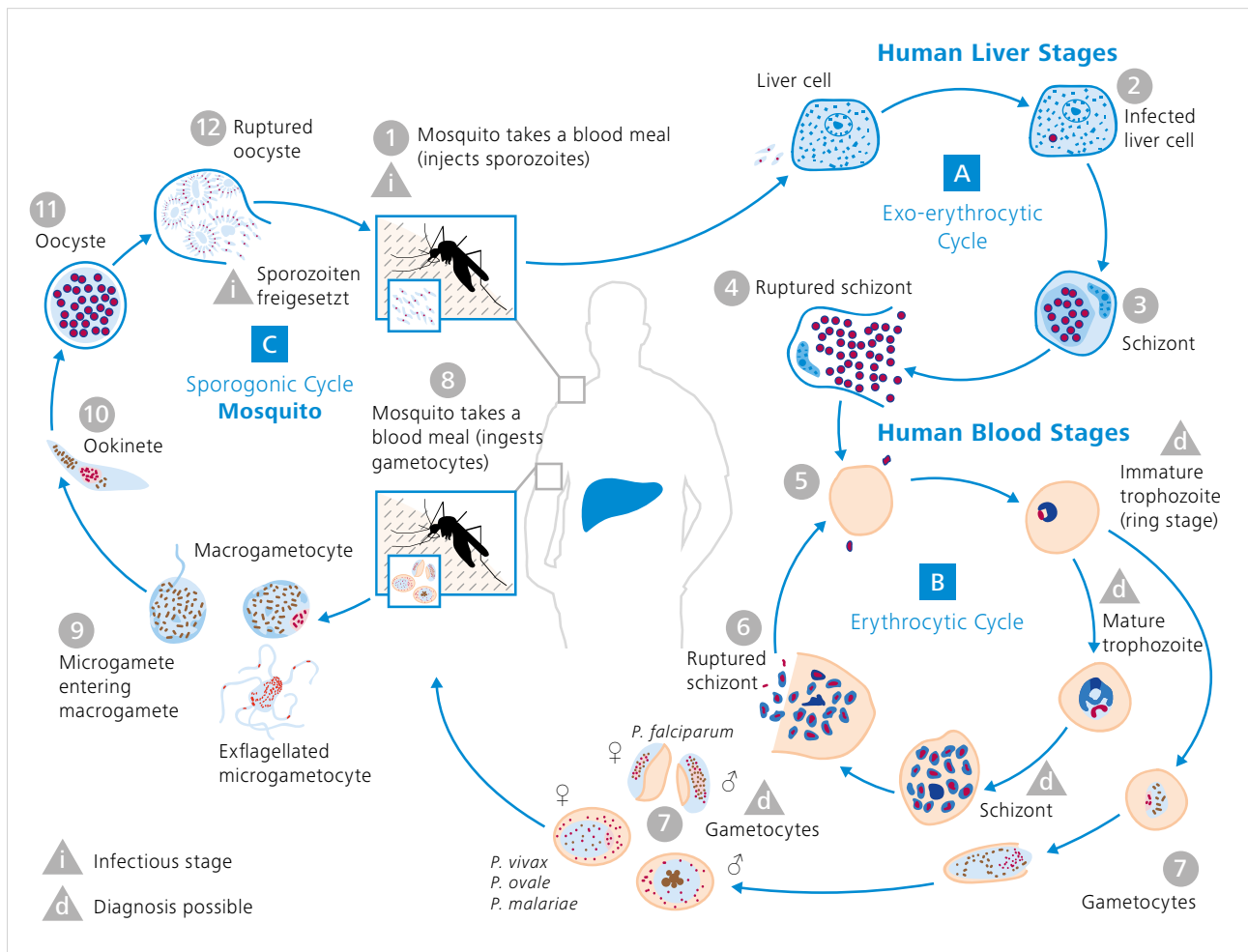


Figure 4 Malaria life cycle

From a histopathological perspective, the fact that many parasitized erythrocytes – e.g. erythrocytes that contain *Plasmodium falciparum* – engorge themselves in cerebral capillaries and appear to block them (Fig.) was already described decades ago. Analyses with electron microscopes revealed that the cell membranes of parasitized erythrocytes exhibit protrusions known as knobs, and that these knobs accumulate on the endothelial cells. Antigens are expressed on the parasitized erythrocytes that bind to the endothelial cells' receptors. This results in microcirculation disorders and endothelial dysfunction. Furthermore, cells of the mononuclear phagocyte system secrete proinflammatory cytokines. In turn, cytokines such as TNF cause an increased number of certain adhesion molecules to be excreted on the endothelial cells in the brain – which in turn intensifies the adherence of parasitized erythrocytes.

Microcirculation disorders, endothelial dysfunction, and the excretion of cytokines like TNF- α are the main pathomechanisms of malignant tertian malaria.

Are There Clear Clinical Signs of Malaria?

The prepatent period (the period of time until the occurrence of trophozoites in the blood) is generally between 7 and 21 days, the incubation period (the period of time until symptoms occur) usually a few days longer. The incubation period can be extended considerably if medicine-based prophylactic treatment is carried out that is not fully effective. As a result of synchronization with the parasite's life cycle, the fever outbreaks can occur in the case of tertian and quartan malaria every 48 hours and 72 hours, respectively.

Symptoms of all forms of malaria include suddenly occurring fever, shaking chills, headache, and aching limbs. Because malaria can cause a wide range of different symptoms, the disease is also referred to as a “master of masquerade.”

In cases of malignant tertian malaria and knowlesi malaria, parasite density can increase rapidly and organ complications can develop – particularly in the brain, the kidneys, and the lungs. Cerebral malaria usually manifests itself as a diffuse encephalopathy with a coma of varying depth and can rapidly lead to death. Acute kidney failure is one of the most common complications, with the kidney failure often leading to death in combination with metabolic acidosis and pulmonary edema.

Detection

Malaria can only be identified if it is considered as a potential cause! Key insights can be gleaned from retrospective analyses of severe cases and cases of death in travelers – in England, delayed detection was a primary risk factor. A study conducted in Switzerland revealed that several patients with malaria who were sent home by their primary care physician without a diagnosis died shortly thereafter without once again visiting a doctor – which demonstrates that the disease must be diagnosed immediately.

Direct detection of the parasite under a light microscope remains the basis for diagnosing the disease today.

Plasmodium can be detected in a blood smear – in the case of low parasite density, a thick blood smear needs to be used to enhance sensitivity.

When carried out correctly, these simple techniques exhibit a high level of sensitivity and specificity. Thanks to its characteristic morphology, plasmodium parasites can be recognized within the red blood cells (intraerythrocytic detection). In both thick and thin blood smears, the chromatin in the cell nucleus appears red-violet; the plasma is blue; and the erythrocytes in the smear are gray. Both the morphology of the infected erythrocytes and the morphology of the parasites play a role in determining the species of plasmodium – the species which cause benign tertian malaria (*P. vivax* and *P. ovale*) can be detected through the increasing enlargement

and loss of color of the infected red blood cells as well as a fine pink dotting (Schüffner’s dots); in contrast, erythrocytes that have been infected with *P. falciparum*, *P. malariae*, or with *P. knowlesi* are neither enlarged nor dotted. In *P. falciparum* infections, blood smears are characterized by only containing young ring forms and a lack of other asexual development stages, such as trophozoites or schizonts. In contrast, in addition to ring forms, all other plasmodium infections exhibit trophozoites and schizonts in the blood smear. If sexual stages are also present (gametocytes), *P. falciparum* is easily differentiated from other plasmodium species due to its typical long, curved shape (banana shape). The ingestion of antibiotics can impact the morphology of the Plasmodium parasites and reduce parasitemia.

Considerable experience is required to prepare and analyze parasitological blood smears, and often only specialized physicians, MTAs, and institutes of tropical medicine possess such experience. That is why physicians who suspect malaria but do not have experience with the disease should immediately send the patient’s blood to a specialized laboratory for analysis. Sending air-dried, unfixed, unstained, thick blood smears and methanol-fixed, unstained, thin blood smears as well as 2 ml of EDTA blood via courier or taxi immediately, even if over long distances, could save the patient’s life. The result should be available within a few hours.

The thick blood smear has the advantage that, due to the lack of fixation and the lysis of individual red blood cells, microscopic analysis of individual parasites can also be carried out in several layers of erythrocytes. Compared to a thin blood smear, the sensitivity for the identification of plasmodium in thick smears is approximately ten times greater. Although the analysis is more difficult, those with experience carrying out such analyses can usually differentiate between the different types of plasmodium in the thick blood smear. It is usually possible to at least differentiate between *P. falciparum* and other plasmodium infections. Viewing the thin blood smear under the microscope provides additional information for species diagnostics. *P. knowlesi* is difficult to differentiate from other types of Plasmodium under a microscope. The microscopic detection limit is 50 parasites per microliter of blood, which corresponds to a parasitemia of under 0.001%.

Technical Procedure

Thin Blood Smear

Giemsa Stain:

Principle: Intraerythrocytic Plasmodium are made visible through staining

Procedure: Spread capillary blood or anticoagulated venous blood (EDTA) on a slide and fix with absolute methanol (for at least one minute). After drying, immerse the slide in Giemsa stain solution for 40 minutes. To freshly prepare the Giemsa stain solution: 1 ml of Giemsa stock solution + 9 ml buffer solution (pH 6.8–7.2), afterwards flush thoroughly with tap water.

Analysis: Standard method

Thick Blood Smear

Procedure: Place a drop of capillary blood (approx. 10 μ l) or anticoagulated venous blood (EDTA) on a slide and mix over approx. 1 cm² in such a way that you can just barely see through the sample. The sample must dry thoroughly and cannot be fixed. Dye the dried, thick smear with Giemsa stain solution (see above) by soaking the slide with the solution for 40 minutes and then subsequently rinsing it carefully with tap water. After drying, it can be viewed under the microscope in oil.

Analysis: Standard method

Quick Dying Process

Thin Blood Smear:

Principle: Quickly dying with ready-made solutions, for example with Diff Quick®.

Procedure: Fix with absolute methanol for one minute, immerse in eosin solution for 10 seconds, rinse with water, immerse in thiazine solution for 30 seconds, rinse with water.

Analysis: Fastest method, but more expensive than Giemsa staining using the standard method and plasmodium parasites are not dyed as well.

Thick Smear:

Rapid staining methods such as Diff-Quick® can also be used: allow the thick smear to air-dry, immerse in the eosin solution for 1 minute, immerse in the thiazine solution for 1.5 minutes, quickly rinse with tap water, allow to dry.

Analysis: Faster, but more expensive than Giemsa staining using the standard method.

Recommended Microscope Equipment

The dyed parasites are typically found and identified using an upright brightfield microscope. Specific characteristics such as Schüffner's dots, for example, can be visualized with high-quality lenses and an appropriate condenser. Typical magnifications of 10x, 20x, and 40x make the initial localization of plasmodium parasites possible. To precisely identify the parasites, high-aperture oil lenses with magnification rates of 63x or 100x are used – typically without coverslip correction (labeled o.D.).

A camera with a high dynamic range, precise image acquisition at the pixel level, and ideally, a cooling module (such as a Peltier cooler) to improve the signal-to-noise ratio is recommended to document the results.



Figure 5 ZEISS Axio Lab.A1



Carl Zeiss Microscopy GmbH
07745 Jena, Germany
microscopy@zeiss.com
www.zeiss.com/routine



Not all products are available in every country. The use of products for medical diagnostic, therapeutic, or treatment purposes may be subject to local restrictions. Contact your local ZEISS representative for more information.
EN_41_013_167 | CZ 02-2018 | Design, scope of delivery, and technical progress subject to change without notice. | © Carl Zeiss Microscopy GmbH